DTI OF THE ISOLATED HUMAN HIPPOCAMPUS AT HIGH SPATIAL RESOLUTION

Shepherd, T. M. (UF, Neuroscience), Ozarslan, E. (UF, Physics), Yachnis, A.T. (UF/MBI), Blackband, S. J. (UF, Neuroscience/NHMFL)

Introduction

In human studies on low field clinical systems it is difficult to resolve individual lamina of the hippocampus with diffusion tensor MRI (DTI). This is desirable since measurement of the diffusivity and fractional anisotropy for individual hippocampal lamina may improve the specificity of DTI for particular hippocampal pathologies. Higher field magnets with strong gradients and more sensitive rf coils offer the capability to obtain DTI data sets at much higher resolutions than possible clinically. This study characterizes DTI contrast in the different lamina of healthy hippocampus autopsy specimens at 60 micron in-plane resolution.

Methods

8-mm coronal segments of hippocampal body were dissected from 5 autopsy specimens (mean age 55.6 ± 6.2 yrs) and immersion-fixed in 20% formalin for 1 week. The samples had short postmortem intervals to fixation (21.2 ± 5.7 hrs) and no evidence for neuropathology. Hippocampi were washed in PBS for 24 hrs, then imaged in Fluorinert™ using a 10-mm birdcage coil inside a 14.1-T Bruker magnet. DTI datasets were obtained with 60 micron in-plane resolution using a multislice pulsed-gradient spin-echo sequence. An image without diffusion-weighting was collected (NEX = 36), then 21 diffusion-weighted images were collected with 415 mT/m diffusion gradients oriented along different directions. These data were used to calculate the apparent diffusion tensor at each image voxel. The mean diffusivity (<D>), fractional anisotropy (FA) and fiber direction then were determined for manually-segmented hippocampal lamina.

Results

FA images demonstrated the laminar anatomy of the hippocampus well. Diffusivity ranged from $1.21 \pm 0.22 \times 10^{-4}$ mm^2/s in the fimbria to $3.48 \pm 0.72 \times 10^{-4}$ mm^2/s in granule cells ($P < 0.001$). The FA of several hippocampal lamina were also statistically different ($P < 0.001$). Color fiber maps (see figure) demonstrated many additional microstructural features of the human hippocampus (e.g. that principal orientation in stratum radiatum is dominated by pyramidal neuron apical dendrites).

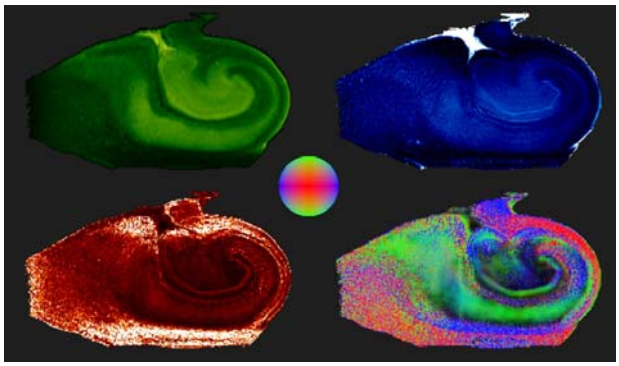

So (top left), <D> (top right), FA (bottom left) and DTI fiber maps (bottom left) from the isolated hippocampus. The FA images and color fiber maps demonstrate the laminar anatomy of the hippocampus

Conclusion

High-resolution DTI provides microstructural information of the human hippocampus. These data can be used to study diffusion-specific changes to particular hippocampal regions to explain signal changes observed with current clinical scanners and may help develop specific MRI surrogate markers for neuropathologies such as Alzheimer's disease or epilepsy. In addition, contrary to previous reports, these data suggest water diffusion in the human CNS is not homogeneous. The work has been submitted to the ISMRM (1).

Acknowledgements

This work was supported by the NIH (RO1 NS36992, P41 RR16105), and the National High Magnetic Field Lab, Tallahassee, FL.

References

1. Shepherd et al., submitted, ISMRM, Miami (2005)